

# Multimodal Hyperspectral Imaging for the Noninvasive Diagnosis of Cervical Neoplasia

---

Daron G. Ferris, MD,\* Raymond A. Lawhead, MD,‡  
Eileen D. Dickman, PhD, MBA,\* Nina Holtzapple, MD,†  
Jill A. Miller, MD,\* Stephanie Grogan, MD,‡ Shabbir Bambot, PhD,§  
Anant Agrawal, MS,§ Mark L. Faupel, PhD§

\*The Departments of Family Medicine and  
†Obstetrics and Gynecology, the Medical College of Georgia, Augusta,  
‡Atlanta Medical Center, Atlanta, and  
§SpectRx, Inc., Norcross, Georgia

## ■ Abstract

**Objective.** To determine the ability of Multimodal Hyperspectral Imaging (MHI) to noninvasively detect, localize and diagnose cervical neoplasia.

**Materials and Methods.** The cervical epithelium was interrogated by MHI using tissue fluorescence and reflectance measurements after the probe was placed on the ectocervix. A Papanicolaou smear was taken, and a colposcopic examination was performed and cervical histologic specimens were collected, when indicated. MHI and Pap smear sensitivity and specificity data were compared with colposcopic and histologic results.

**Results.** Nineteen patients had CIN2 or higher, 30 had CIN1, 34 had benign cellular changes or metaplasia, and 28 were normal by both Pap smear and colposcopic examination. At equal specificity (70%) for both tests, the sensitivity of MHI was 97%, compared to 72% for the Pap smear.

**Conclusion.** MHI detected cervical cancer precursors at a rate greater than that obtained by a simultaneously collected Pap smear. ■

**Key Words:** cervical neoplasia, noninvasive diagnosis, Multimodal Hyperspectral Imaging, Papanicolaou smear

Health care professionals encounter multiple dilemmas with the surveillance, diagnosis, and management of women with cervical neoplasia. An imperfect screening test, a lengthy Papanicolaou (Pap) smear collection to notification interval, and a substantial patient noncompliance rate with recommended practices may all adversely impact the screening process [1–8]. Cervical neoplasia is suspected from an abnormal screening Pap smear or positive triage test for oncogenic human papillomavirus (HPV) DNA that is localized and detected by specific epithelial features noted during colposcopic examination of the lower genital tract. The diagnosis is confirmed by histologic results obtained from sampling the ectocervix and endocervical canal, when deemed necessary [9]. When results from these evaluations are considered collectively, optimal management ensues. Most of the tests involve a subjective appraisal that varies considerably and depends on specimen or anatomic variation, as well as evaluator expertise. Thus, diagnoses may be influenced adversely by technical issues and are not made consistently at an expert level; the diagnoses also are not always reproducible.

Reprint requests to: Daron G. Ferris, MD, Medical College of Georgia, 1423 Harper Street, HH-105, Augusta, Georgia 30912

A simple instrument designed to rapidly render an accurate, cost-effective, on-site clinical diagnosis following a brief noninvasive biophotonic interrogation of the cervical transformation zone may improve cervical cancer prevention. A noninvasive cervical neoplasia detection system based on fluorescence spectroscopy has been shown to perform better than colposcopy, cervicography, cervical cytology, and HPV testing, which are all current methods used to screen, triage, and diagnose cervical neoplasia [10]. Furthermore, the inclusion of fluorescence spectroscopy in the diagnosis and management of women with cervical neoplasia may be more cost-effective than current traditional approaches [11].

Fluorescence and reflectance technology depends on biomolecular and morphologic indicators of disease. Fluorescence-based systems rely on the propensity of certain cell components, known as fluorophores (e.g., tryptophan, flavins, collagen), to emit light when excited by specific wavelengths of light, with the peak intensity in a different, but corresponding frequency band [12, 13, 14, 15, 16]. The actual amount of light emitted by fluorophores is exceedingly small, on the order of nanowatts, requiring an extremely sensitive photodetection system. Theoretically, certain early metabolic changes may be detected by fluorescence spectroscopy as neoplasia develops. Reflectance techniques attempt to characterize tissue by measuring the amount and wavelengths of light reflected back to a sensitive photodetector when the tissue is exposed to a broadband light source. In this way, morphologic features of neoplasia, such as nuclear content, epithelial thickening, and neovascularization, may be detected as light is differentially absorbed, scattered, and reflected. Tissue fluorescence and reflected light measurements are analyzed using computer-based algorithms to determine whether the tissue is normal or abnormal; however, these systems have not been studied extensively [14, 17, 18]. The purpose of this study was to determine the feasibility of a Multimodal Hyperspectral Imaging (MHI) system to detect, localize, and diagnose cervical neoplasia in women.

## MATERIALS AND METHODS

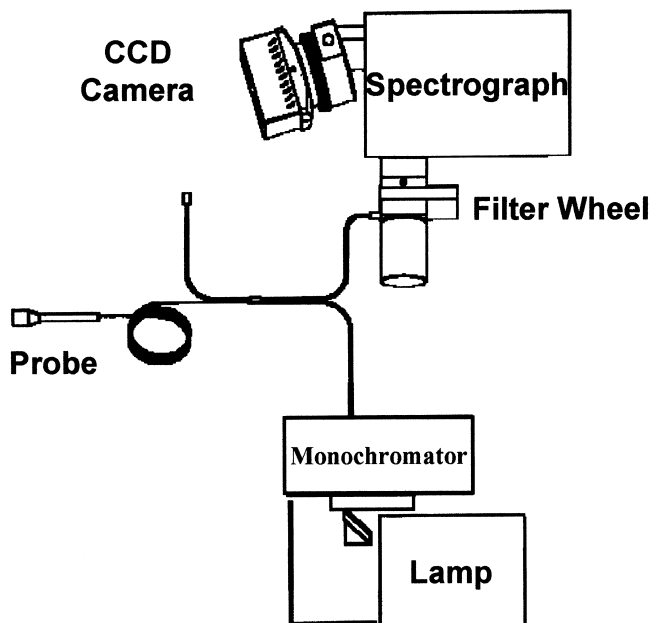
After obtaining internal review board-approved informed consent, nonpregnant women 18 years of age or older with an intact cervix who presented consecutively for a colposcopic examination were enrolled at one of two clinical sites: Atlanta Medical Center, Atlanta, and the Medical College of Georgia, Augusta, Georgia. Although the majority of women presented with a history of an abnormal Pap smear within the previous 3 months,

some women were included if scheduled for an electro-surgical loop excision, cryotherapy, hysterectomy, or a colposcopic examination following prior excisional or ablative treatment for cervical neoplasia.

The prototype MHI system consisted of a lamp source and computer-controlled monochromator system for projecting selected wavelengths of light onto the cervix through a fiber optic probe (see Fig. 1). The custom fiber optic probe was encased in a disposable plastic sheath. The light emission/collection fibers embedded in the probe were designed to maximize the amount of spatial coverage of the ectocervix while at the same time minimizing the amount of potential crosstalk between fiber pairs.

This system employs both fluorescence and reflectance tissue excitation with a multichannel spectrograph capable of hyperspectral resolution of about 5 nm and spatial resolution of the ectocervix of about 1 mm. A CCD camera, spectrograph, and filter wheel assembly, also under computer control, were used for collecting the resultant light emitted from and reflected by the cervix.

A video colposcope and attached image management system (Welch Allyn, Skaneateles Falls, New York) were used to perform colposcopy and digitally capture cervical images for annotation and documentation purposes



**Figure 1.** The Multimodal Hyperspectral Imaging Fiber Optic System Prototype consists of an electro-optic system (Xe-arc lamp and a detection assembly) and a bifurcated fiber optic probe to send excitation light in one arm and collect the tissue emission in the other.

[19, 20]. A small round paper dot and surgical marking pen were used to provide temporary landmarks for spatial alignment of colposcopic and spectroscopic images.

### Study Design

Women presenting consecutively for a colposcopic examination were told about the study and asked to enroll. After signing the IRB-approved informed consent document, affirming nonpregnant status by a urine pregnancy test and obtaining demographic data, the cervix was visualized using the videocolposcope.

A small round paper dot was applied to the cervix at 12 o'clock and a surgical ink pen was used to mark the cervix at the 3 and 9 o'clock positions. A digitized colposcopic image was then obtained to document these reference points. After MHI calibration, the end of the fiber optic spectroscopic probe was applied over the ectocervix and the proximal end was affixed to a customized vaginal speculum. Thereafter, the cervix was interrogated for approximately six minutes using the MHI device.

Following the multiple spectroscopic measurements, a Pap smear was obtained and a colposcopic examination conducted, including cervical biopsy and endocervical curettage, when indicated. Pathologic specimens were interpreted by pathologists at each clinical site. In the case of women scheduled for electrosurgical loop excision or hysterectomy, no cervical biopsies were obtained, but rather the postoperative histologic specimen was examined. Colposcopists recorded whether the examination was satisfactory or not, and provided a colposcopic impression. Biopsy sites were annotated on the previously obtained digitized cervical images and the subject was questioned about any adverse events experienced with the MHI procedure.

### Statistical Analyses

The spectroscopic and cytologic results were compared with those of biopsy and colposcopy to determine the sensitivity, specificity and receiver operating characteristic (ROC) curves of the device and Pap smear. Key discriminative parameters included measures of central tendency (e.g., median) and dispersion (e.g., interquartile range) that were calculated for each patient's spectroscopic measurements from each measured point on the cervix. Principal components analysis was used to identify key discriminative features in the spectroscopic data [21]. Linear discriminant analysis of these features, both for the entire cervix and within defined cervical quadrants, was employed to determine the effectiveness

of MHI to discriminate lesions at two disease thresholds,  $\geq$ CIN2 and  $\geq$ CIN1. Confidence intervals and resampling cross validation techniques were used to evaluate the robustness of the results [22]. Subject history variables (e.g., age, parity, prior surgery of cervix, adequacy of colposcopic examination, colposcopic impression) were analyzed using Fisher's exact tests to determine their effect on MHI diagnoses.

### RESULTS

A total of 136 women were enrolled in the study, and data from 111 of these women were included for analysis. Of the 25 women excluded from analysis, 18 were excluded because of an MHI system malfunction (either the illumination source was not activated or the source shutter remained closed) and, thus, no resultant spectroscopic data were available. The remaining seven were excluded because no colposcopic or histologic data were available or the subjects chose to exit the study prior to data collection.

Subjects ranged in age from 18 to 73 (median = 30). Thirty-one percent (34 of 111) of the subjects were nulliparous. Fifty-one percent (57 of 111) of subjects had a prior history of cervical surgery. The colposcopic exam was satisfactory for 53% (59 of 111) of subjects. Of the 111 subjects included for analysis, 19 had CIN2 or more severe, 30 had CIN1, 34 had non-neoplastic changes (e.g., metaplasia, infection, repair) identified either by colposcopy ( $n = 30$ ) or histopathology ( $n = 4$ ), while 28 had cytologically and colposcopically normal cervixes.

For analysis by cervical quadrant, the lesion location could be identified both colposcopically and spectroscopically for nine  $\geq$ CIN2 containing quadrants and 21  $\geq$ CIN1 containing quadrants. These were compared with 128 nondysplastic quadrants and 102 normal quadrants. The means and standard deviations for a fluorescence index and a reflectance index as a function of cervical status are shown in Figure 2. Both indices increase with increasing severity of disease. The observed spectral differences between CIN1 and CIN2/3, and the normal cervix were statistically significant (Mann-Whitney U test;  $p < .001$ ) for both fluorescence and reflectance indices.

Figures 3 and 4 provide a visual indication of the trends that gave rise to the aforementioned statistically significant results. In Figure 3, a normal cervix is seen with both an image captured by the video colposcope (with marking dots on cervix) and a corresponding false-color fluorescence map of the same cervix. A cer-

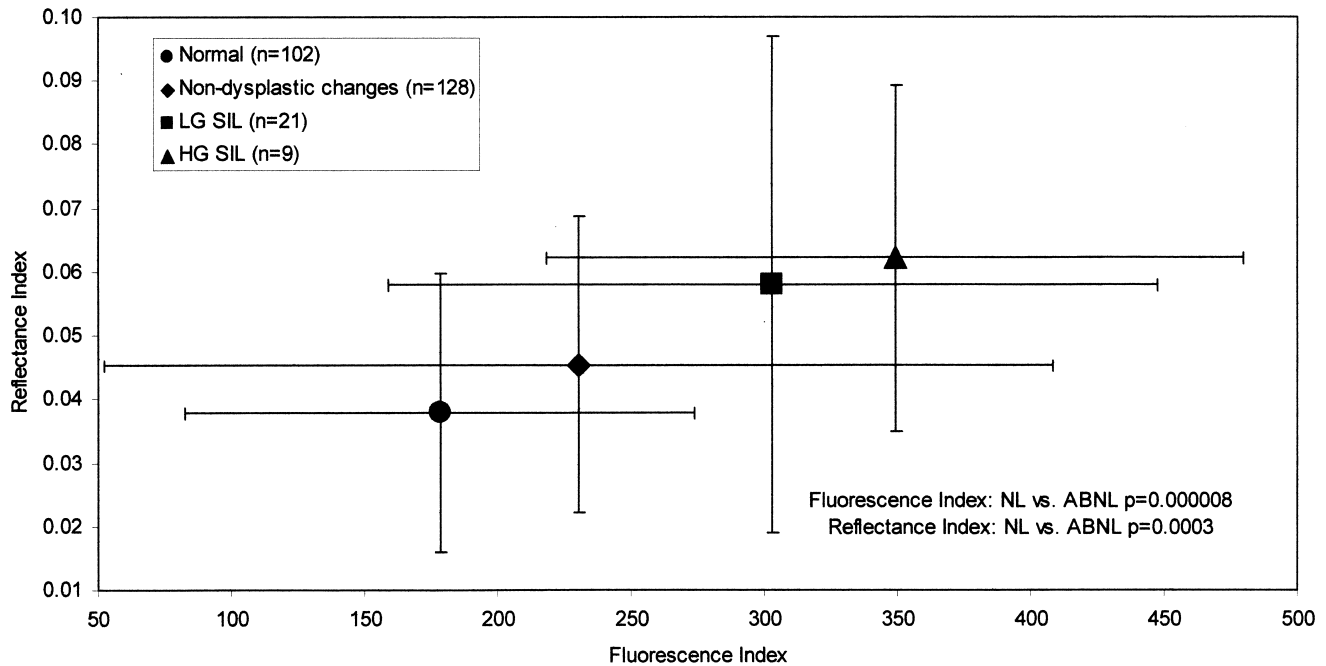


Figure 2. Cervical status based on mean reflectance index versus fluorescence index results, including standard deviations.

vix with CIN2 is seen in Figure 4. The white and yellow areas of the MHI image denote the corresponding areas of CIN2. These fluorescence maps demonstrate increasing heterogeneity across the cervix and increasing intensity of the “signal” in localized areas of the cervix as severity of neoplasia increases.

Principal components analyses utilizing measures of central tendency (e.g., median) and dispersion (e.g., interquartile range) that were calculated from the array of each subject’s spectroscopic measurements were performed for both the whole cervix (“whole cervix analysis”) and for diseased quadrants (“quadrant analysis”). ROC curves based on logistic regression of these measures were then generated and compared with the Pap smear ROC curve. The results of the whole cervix analysis with a positive disease cutpoint set at  $\geq$ CIN2 are seen in Figure 5. The area under the ROC curve for the MHI test was 94.7% compared with 77.8% for the Pap smear.

At equal specificities for both tests (i.e., 70%), the MHI test had an area under the ROC curve of 97% compared with the Pap smear area under the ROC curve of 72%. Thus, MHI showed an increased detection rate for  $\geq$ CIN2 disease of 25% greater than that of the Pap smear. The results of the whole cervix analysis, with a positive disease cutoff set at  $\geq$ CIN1, demonstrated the area under the ROC curve for the MHI test (at the CIN1

threshold) was 93.3% compared with 71.8% for the Pap smear (Figure 6). At equal specificities for both tests (i.e., 70%), the MHI test had a sensitivity of 95% compared with the Pap smear sensitivity of 64%. When analysis of the MHI test was restricted to diseased versus nondiseased quadrants, the area under the ROC curve for the CIN2 threshold was 98.0% and 93.4% for the CIN1 threshold. Caution should be exercised when interpreting the quadrant analysis using the CIN2 threshold, since there were only nine cases in the disease category of  $\geq$ CIN2. The results of the ROC analyses as a function of disease threshold and area of cervix analyzed are shown in Table 1.

We also performed two types of resampling cross-validation analyses for the whole cervix data (using the CIN2 threshold) in order to simulate prospective performance of the logistic regression model. The bootstrap cross-validation model produced a 94.8% area under the ROC curve and cross-validation using repeated sampling of 80% of the data for training and 20% for testing produced an area under ROC curve of 92.4%. Both values lie within the 95% confidence interval of 90.6% to 98.9% shown for the CIN2 threshold, whole cervix analysis summarized in Table 1.

Five subject history variables were analyzed (age, parity, prior cervical surgery, colposcopic adequacy, and colposcopic diagnosis) to determine their effect on

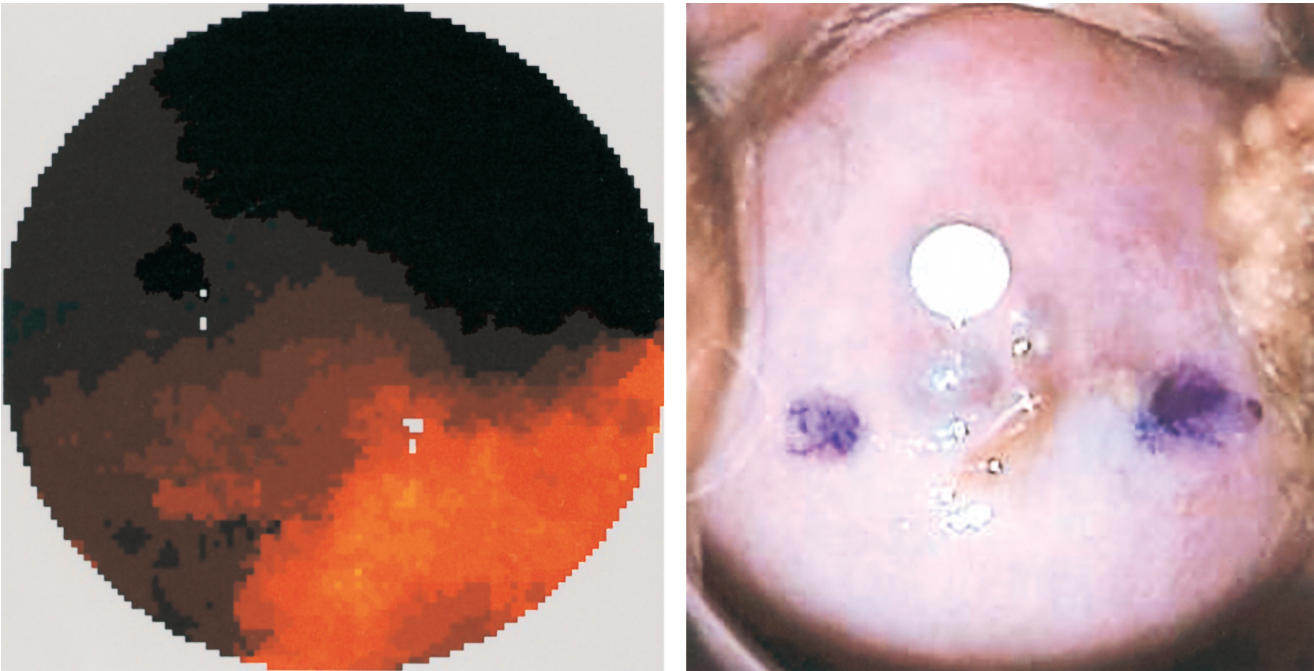


Figure 3. A fluorescence map and colposcopic cervical image of a normal cervix. The small paper dot and ink marks were placed for referencing purposes.

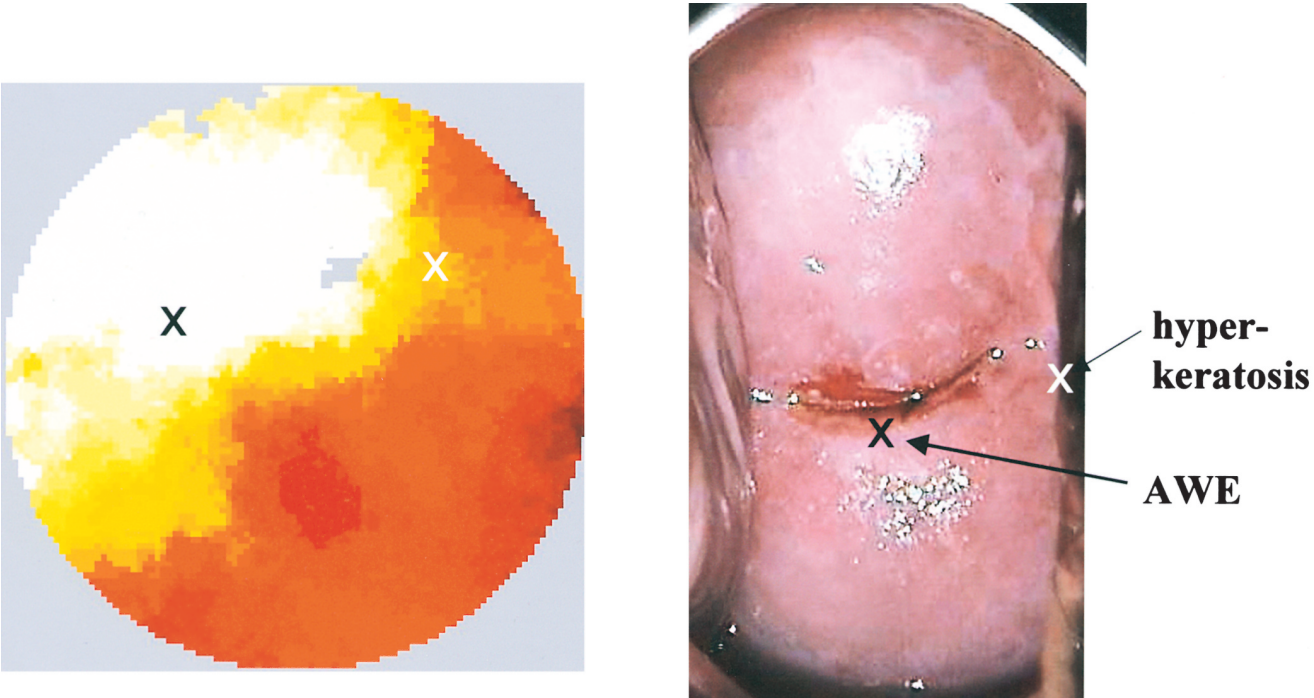
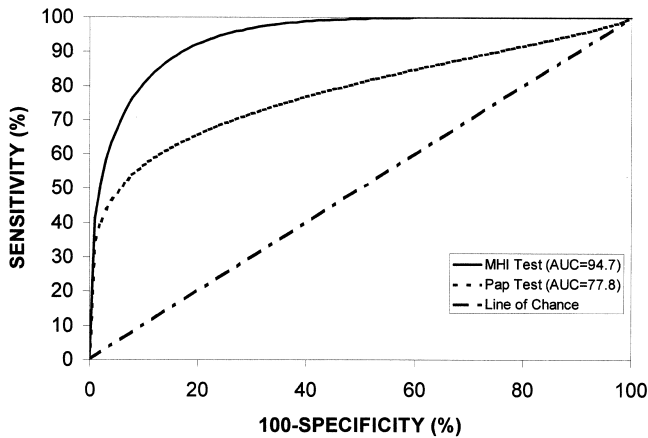


Figure 4. A fluorescence map and colposcopic cervical image of CIN2. The "X" marks the biopsy site in each image. The white area represents the area of neoplasia.



**Figure 5.** The MHI and Pap smear ROC results of the whole cervix analysis with a positive disease cutoff of  $\geq$  CIN2.

MHI results and only adequacy of the colposcopic examination at the CIN1 threshold exerted a statistically significant effect. Specifically, 42.3% of the subjects free of neoplasia and with a satisfactory colposcopic examination had a false positive MHI result while only 15.6% of the subjects with an unsatisfactory colposcopic examination had a false positive result by MHI, a difference which was marginally significant (Fisher's Exact Test;  $p = .04$ ).

Thirteen of the 134 subjects (9.7%) enrolled in the study reported some type of minor adverse experience induced by the MHI procedure. Pressure and a pinching sensation were the most common complaints recorded. No serious or unexpected adverse events were reported.

## DISCUSSION

Multimodal hyperspectral imaging was able to discriminate high grade ( $\geq$ CIN2) cervical lesions from less severe lesions (CIN1) and normal cervical tissue. Furthermore, when the positive disease cutoff was lowered

to  $\geq$  CIN1, MHI was still able to discriminate neoplastic from normal tissue. Proper discrimination is critically important to ensure optimum screening and management. Overdiagnosis burdens the health care system with excessive costs and adversely impacts women with unnecessary anxiety, morbidity, and wasted time. Colposcopists have difficulty discriminating some cases of CIN1 from immature metaplasia based on similar visual findings of translucent acetowhite epithelium; fine caliber, closely spaced blood vessels; irregular margins; and negative iodine staining. Some pathologists also experience difficulty differentiating the two entities because of nuclear and cellular similarities. We were unable to determine whether MHI could effectively discriminate CIN1 from immature squamous metaplasia and larger trials must eventually address this issue.

When subjected to ROC curve analysis, MHI was shown to detect CIN better than a simultaneously obtained Pap smear. In fact, MHI increased the detection of cervical neoplasia by a minimum of 25% when compared with the Pap smear whether a  $\geq$ CIN2 or  $\geq$ CIN1 disease threshold was considered. Most importantly, this increased sensitivity was achieved without a reduction of specificity. Therefore, MHI may in the future provide clinical utility by augmenting cervical cytology. Because of the small sample size and selected population, it is unknown from these data whether MHI could be used for primary screening. If MHI is to be used for primary screening purposes or as an adjunct test, clinical trials will need to be conducted in a universal screening population and not a high-risk-colposcopy clinic population. These data are especially impressive considering the fact that the MHI test examined only the ectocervix, while the Pap smear sampled both the endocervical canal and ectocervix. Once an endocervical probe, currently undergoing early clinical testing, is available, one

**Table 1. Results of ROC Analysis for MHI**

Disease Threshold <sup>1</sup>	Area of Cervix <sup>2</sup>	Area under ROC curve (95% CI) <sup>3</sup>	Optimized Sensitivity <sup>4</sup>	Optimized Specificity <sup>5</sup>
CIN 2 <sup>6</sup>	Whole <sup>7</sup>	94.7 (90.6, 98.9)	95%	83%
CIN1	Whole	93.3 (89.1, 97.7)	88%	86%
CIN2	Quadrant <sup>8</sup>	98.0 (96.3, 97.6)	100%	95%
CIN1	Quadrant	93.4 (89.3, 97.6)	87%	88%

<sup>1</sup>Positive test cutoff  $\geq$  to level of neoplasia

<sup>2</sup>Area of cervix for which diagnostic indices were calculated

<sup>3</sup>Percentage of area beneath ROC curve including 95% confidence interval

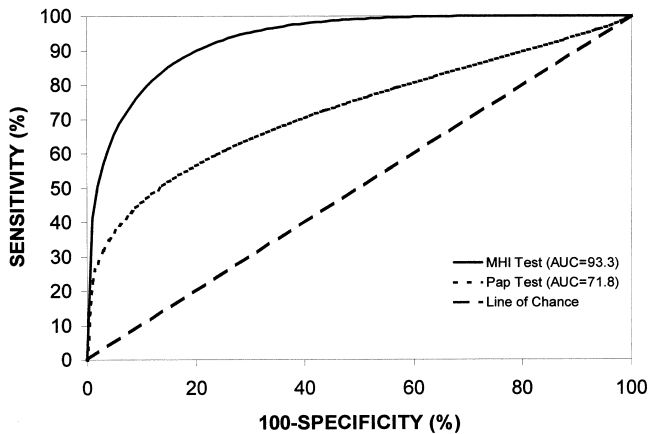
<sup>4</sup>Point on ROC curve indicating sensitivity where the sum of sensitivity and specificity are maximized

<sup>5</sup>Point on ROC curve indicating specificity where the sum of sensitivity and specificity is maximized

<sup>6</sup>Cervical Intraepithelial Neoplasia 2

<sup>7</sup>Entire cervix considered

<sup>8</sup>Single quadrant of cervix considered



**Figure 6.** The MHI and Pap smear ROC results of the whole cervix analysis with a positive disease cutoff of  $\geq$  CIN1.

may anticipate enhanced MHI performance derived from augmented sampling. However, the ability of MHI to detect glandular neoplasia located deeply within gland clefts remains unknown. Of note, few women reported discomfort with use of the MHI fiber optic probe. Except for the increased time required for interrogation, it would appear that the probe may be no more uncomfortable for women than collection of a Pap smear. A noncontact MHI camera system, currently undergoing clinical study, may further minimize cervical cancer surveillance discomfort.

Fluorescence and reflectance mapping of cervical neoplasia may have some value as a colposcopy adjunct. MHI appeared able to identify lesions and determine their extent as is required during colposcopy. This feature may be useful when evaluating women with large, complex lesions, particularly for novice colposcopists. We are presently working to increase the spatial resolution of MHI while maintaining the optimal spectral information required for disease detection. More sophisticated appraisal of mapping with accurate histologic/spectroscopic correlation is still necessary to determine the true precision and reliability of this feature.

Although other researchers have used fluorescence and reflectance mapping of the cervix to detect cervical neoplasia, those interrogations have been limited by the use of only a few emission wavelengths, a small and limited subject population, and in some cases, the interrogation of only a small portion of the cervix [14, 15, 17, 18]. In our study, we sought to include a variety of women with varying disease and nondisease states, in order to better test the algorithms. Further, we collected maximum data from the cervix by not only scanning the

entire cervix, but also by using a multitude of wavelengths, including both UV and visible light. Therefore, our system may be better able to detect subtle differences on the cervix that may have been missed by other systems.

Our conclusions also are limited by a relatively small sample size that included a minimal number of cases of high-grade disease and cervical cancer. Moreover, our population was young, reflecting a group of women in which the transformation zone was more likely to be seen clearly on the ectocervix. However, 47% of colposcopic examinations in our population were judged to be unsatisfactory and false positive rates for MHI were actually significantly lower in subjects whose colposcopic examination was unsatisfactory compared with those whose colposcopic examination was satisfactory. This preliminary finding may reflect difficulty in discriminating immature squamous metaplasia from true neoplasia.

Other factors in this study which may influence the ability to estimate the true performance of MHI were that histopathology was determined by clinical center pathologists and not an expert panel, and that most disease was detected based on the skills of colposcopists and not pathologic evaluation of a larger specimen obtained from conization or hysterectomy. The latter process may alter the perceived performance of MHI. The potential effects of blood and cervical infection on MHI interpretation are unknown and need further evaluation. Finally, from a clinical perspective, the prototype equipment was cumbersome in size, slow in interrogation and will require user interface improvements. Attention to these ergonomic issues is necessary for such equipment to be adopted by health care providers.

### Acknowledgments

This study was funded by a grant from SpectRx Inc., Norcross, Georgia, and supported by Welch Allyn, Skaneateles Falls, New York. We appreciate the additional assistance from Michael Macfee, MD, Lisa D. Woodward, RN, Candis Kapsner RN, Fan Xu, MS, Tim Harrell, MS, Gita Giddons, RN, Terry Arrington, and April Dean.

### REFERENCES

1. Koss LG. The Papanicolaou test for cervical cancer detection. A triumph and tragedy. *JAMA* 1989;261:737-43.
2. Campion MJ, Ferris DG, DiPaolo F, Reid R, Miller MD. *Modern Colposcopy, A Practical Approach*. Augusta, Georgia: ESI, 1991.



3. CDC. Cervical cancer control—Rhode Island. *MMWR* 1989;38:659–62.
4. Laedtke TW, Dignan M. Compliance with therapy for cervical dysplasia among women of low socioeconomic status. *So Med J* 1992;85:5–8.
5. Martin PL. How preventable is invasive cervical cancer? A community study of preventable factors. *Am J Obstet Gynecol* 1972;113:541–8.
6. Stewart DE, Buchegger PM, Lickrish GM, Sierra S. The effect of educational brochures on follow-up compliance in women with abnormal Papanicolaou smears. *Obstet Gynecol* 1994;83:583–5.
7. Evidence report/technology assessment number 5, Evaluation of cervical cytology. Rockville, MD; Agency for Health Care Policy and Research, February, 1999; US Department of Health and Human Services AHCPR Publication No. 99-E010.
8. Fahey MT, Irwig L, Macaskill P. Meta-analysis of Pap test accuracy. *Am J Epidemiol* 1995;141:680–9.
9. Ferris DG. Colposcopy. In: Ferris DG, ed. *Primary Care: Clinics in Office Practice; Office Procedures*. Philadelphia, PA: W.B. Saunders, 1997.
10. Mitchell MF, Cantor SB, Ramanujam N, Tortolero-Luna G, Richards-Kortum R. Fluorescence spectroscopy for diagnosis of squamous intraepithelial lesions of the cervix. *Obstet Gynecol* 1999;93:462–70.
11. Cantor SB, Mitchell MF, Tortolero-Luna G, Bratka CS, Bodurka DC, Richards-Kortum R. Cost-effectiveness analysis of diagnosis and management of cervical squamous intraepithelial lesions. *Obstet Gynecol* 1998;91:270–7.
12. Ramanujam N, Mahadevan A, Mitchell MF, Thomsen S, Silva E, Richards-Kortum R. Fluorescence spectroscopy of the cervix. *Clin Consultations Obstet Gynecol* 1994;6:62–9.
13. Ramanujam N, Mitchell MF, Mahadevan A, Thomsen S, Silva E, Richards-Kortum R. Fluorescence spectroscopy: A diagnostic tool for cervical intraepithelial neoplasia (CIN). *Gynecologic Oncol* 1994;52:31–8.
14. Ramanujam N, Mitchell MF, Mahadevan A, Thomsen S, Silva E, Richards-Kortum R. In vivo diagnosis of cervical intraepithelial neoplasia using 337-nm-excited laser-induced fluorescence. *Proc Natl Acad Sci USA* 1994;91:10193–7.
15. Ramanujam N, Mitchell MF, Mahadevan-Jansen A, Thomsen SL, Staerckel G, Milpica A, Wright T, Atkinson N, Richards-Kortum R. Cervical precancer detection using multivariate statistical algorithm based laser-induced fluorescence spectra at multiple excitation wavelengths. *Photochem and Photobiol* 1996;64:720–35.
16. Richards-Kortum R, Mitchell MF, Ramanujam N, Mahadevan A, Thomsen S. In vivo fluorescence spectroscopy: Potential for non-invasive, automated diagnosis of cervical intraepithelial neoplasia and use as a surrogate endpoint biomarker. *J Cellular Biochem* 1994;19:111–9.
17. Parker MF, Mooradian GC, Karins JP, et al. Hyper-spectral diagnostic imaging of the cervix: Report on a new investigational device. *J Lower Gen Tract Dis* 2000;4:119–24.
18. Burke L, Niloff J, Kobelin M, Abu-Jawdeh G, Zelenchuk A, Modell M. Use of autofluorescence of cells to evaluate cervical neoplasia. *J Gynecol Tech* 1996;2:187–90.
19. Ferris DG, Ho TH, Guijon F, Macfee, MS, Guerra, DMM, Barrasso R, et al. A comparison of colposcopy using optical and video colposcopes. *J Lower Gen Tract Dis* 2000;4:65–71.
20. Ferris, DG. Videocolposcopy. *J Lower Gen Tract Dis* 1997;1:15–8.
21. Fisher LD, Van Belle G. *Biostatistics: A Methodology for the Health Sciences*. New York: John Wiley and Sons, 1993:692–762.
22. Efron B, Tibshirani R. Statistical data analysis in the computer age. *Science* 1991;253:390–5.